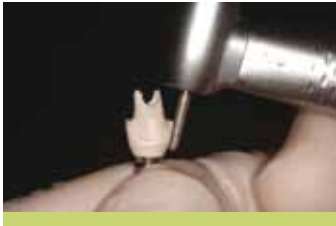
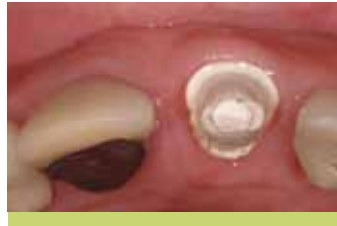
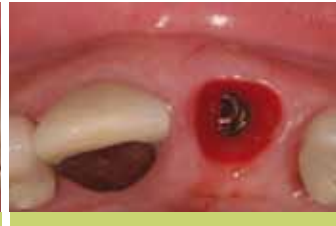CUSTOMIZED IMPRESSION POST FOR BONE LEVEL IMPLANTS



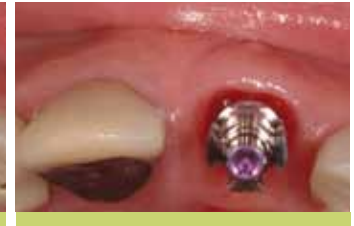1. Prepare customized temporary abutment to meet your desired emergence profile.



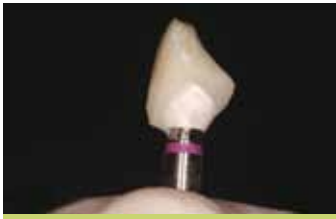2. The desired emergence profile for the implant will be achieved with the provisional.



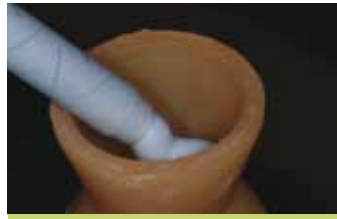3. Now that the emergence profile has been developed, you will now want to capture this same emergence profile when taking a final impression.



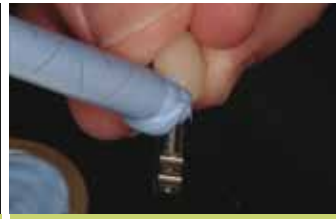4. A stock impression post must be customized to capture soft tissue emergence profile.



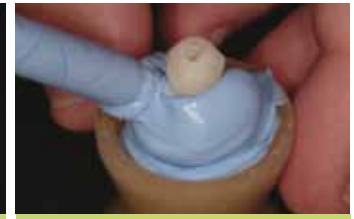5. Connect custom temporary abutment and provisional to implant analog.



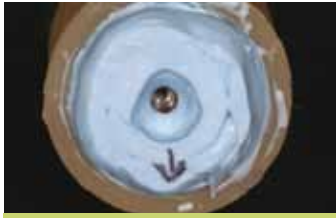6. Fill small vessel with bite registration material, such as Blu-Mousse®.



7. Apply bite registration material to the abutment and analog to ensure a complete impression is taken.



8. Embed the temporary abutment, provisional and implant analog into the bite registration material. Once material sets, remove provisional and temporary abutment.



9. Notice the transfer of the shape of the temporary into the material. Mark the buccal position for orientation.



10. Connect impression coping to implant analog in bite registration material.



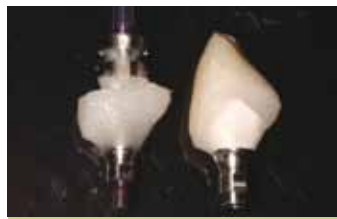11. Fill the impression with cold cure or auto-polymerizing rapid cure temporary material.



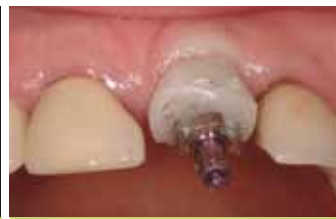12. Let temporary material cure.



13. Unscrew temporary post and trim excess material. Fill any voids, polish and take impression.






14. Notice the matching emergence profile of the temporary abutment and impression post.






15. Screw the custom impression post into the implant and take impression. Once impression material sets, unscrew the impression post and remove impression. The master cast is now ready to be fabricated after the lab analog has been placed into the impression.

RC COMPONENTS

025.4202		RC Impression post, with guide screw
024.4370		RC Temporary meso abutment D 7.0 mm
025.4101		RC Implant analog

NC COMPONENTS

025.2202		NC Impression post, with guide screw
024.2370		NC Temporary meso abutment D 5.0 mm
025.2101		NC Implant analog

Photos courtesy of: Samuel Zfaz, DDS – Fred Norkin, DMD – Jeffrey Ganeles, DMD